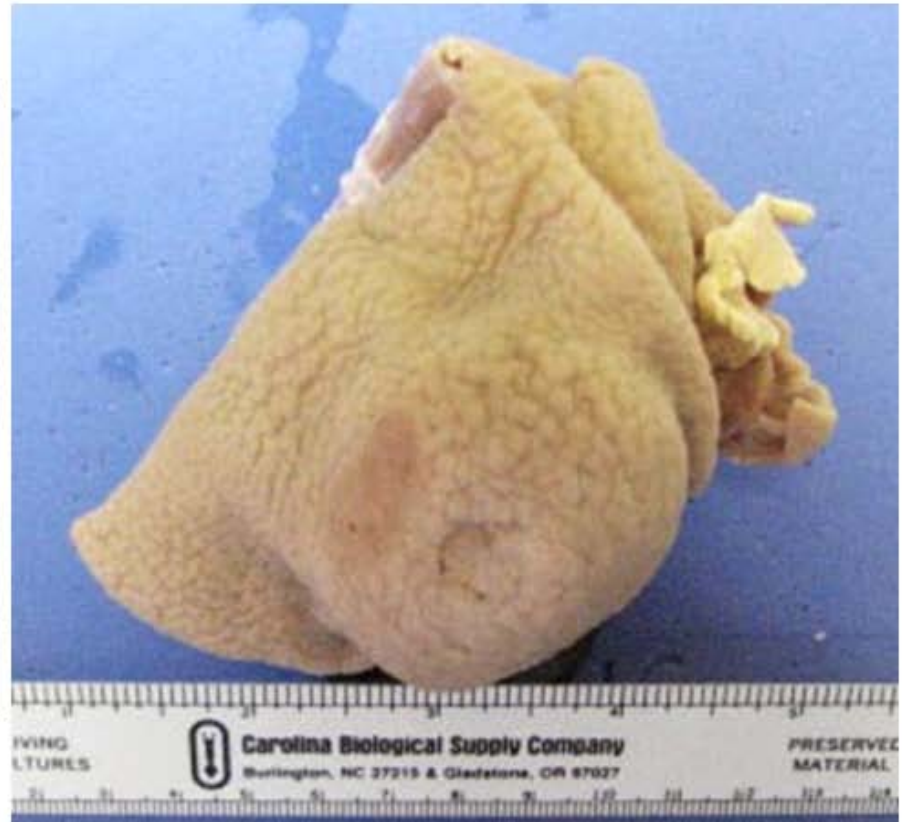
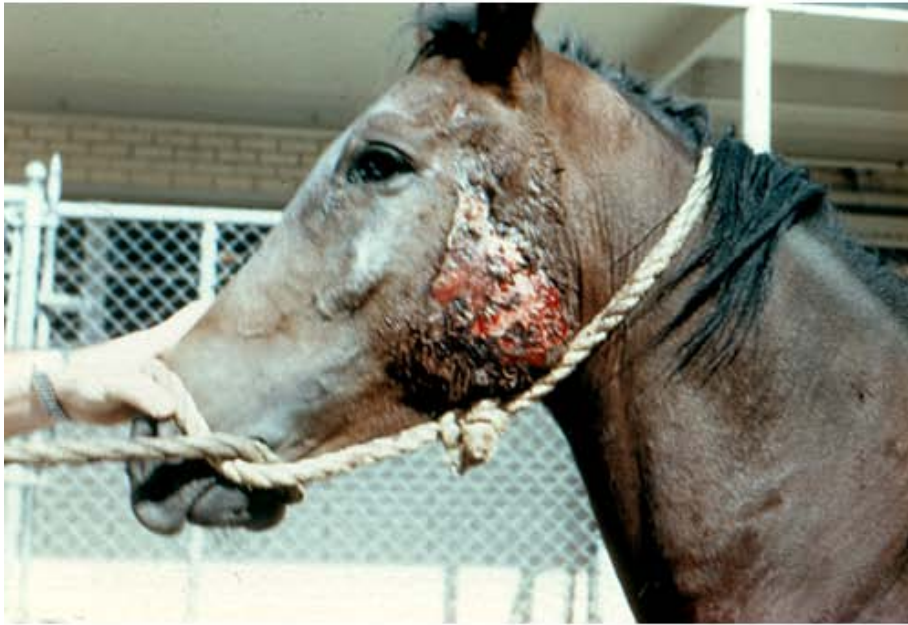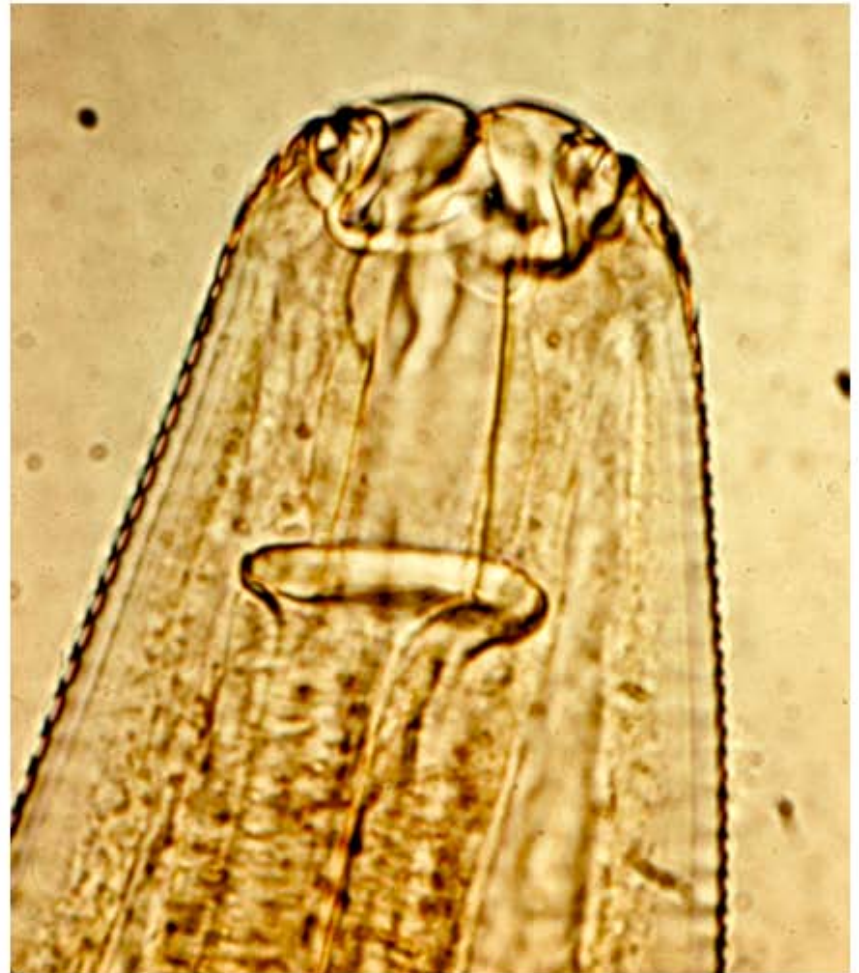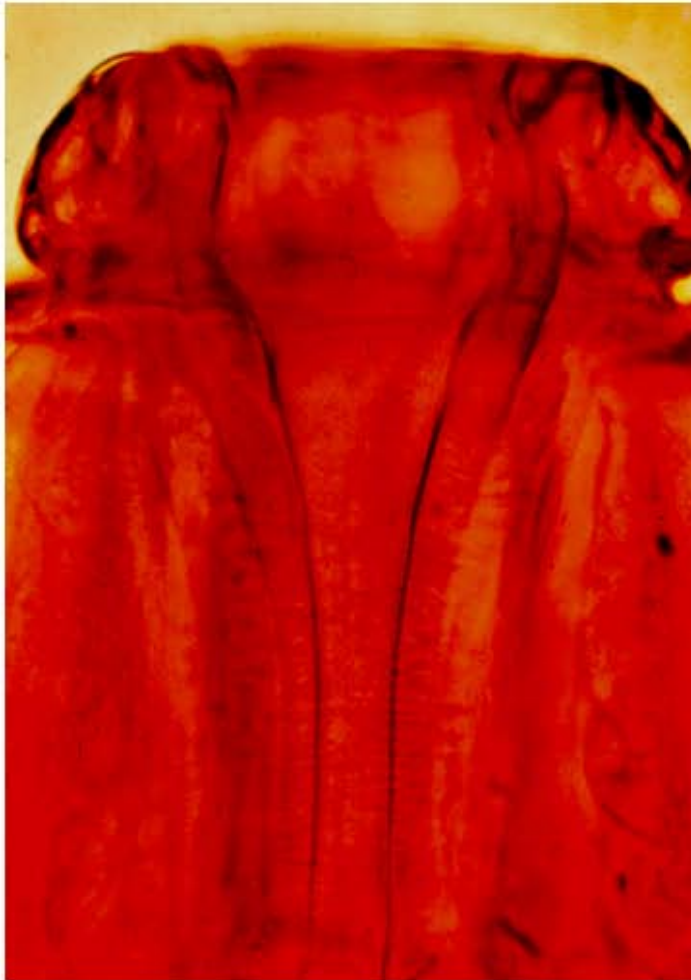


Note: Materials in this presentation are from the veterinary parasitology collection, Texas A&M University, College of Veterinary Medicine (1970).

Gross pathology. Cutaneous habronemiasis (summer sores), left; “golf-ball” size stomach tumor caused by *H. megastoma*, right.



Funnel-shaped walls of buccal capsule in *Habronema megastoma*, left; parallel buccal capsule walls of *H. microstoma* or *H. muscae*, right.





*Habronema* eggs in horse fecal sedimentation. Note elongate egg with very thin shell wall and characteristic “fold” of larva.

